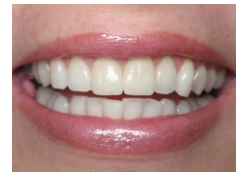




## Optimal Restorative Success: Chairside Tips

**Q:** Steve, I have a patient who wants to increase the length of her upper anteriors. She is very concerned the restorations will look natural and enhance her smile. How can I best communicate to you the patient's and my expectations?

**A:** Before numbing the patient, take two photos of her full smile, one full face and one close-up, showing the full lips and teeth with lips unretracted and teeth slightly apart to show the occlusal plane and incisal length in relation to the lips. Take an impression for pre-op and/or post-op full arch study casts, discuss any improvements you and the patient would like and note changes on the laboratory work order. Also, now you can check the case before it is finished. At Killian Dental, you can view the restoration from your computer over the internet in a live, real-time meeting via high resolution, close-up camera to see the contours of the diagnostic wax or the preliminary bisque ceramic before the case is finalized. **For a more detailed discussion regarding photographic communication, go to [www.killiandental.com](http://www.killiandental.com) and click-on "Resource Library", then under the heading of "Photography" select "Communicate with your Technician".**

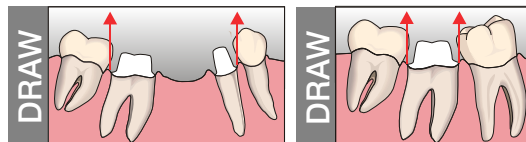


**Q:** I typically provide my lab with a bite registration that covers both the prep and some of the adjacent dentition. I believe the registration is very accurate. However, I am having to adjust the occlusal surface of posterior restorations more than should be necessary. The restoration appears to have good occlusal clearance on the model, but the lab may not have articulated the case correctly. How can I help my lab ensure an accurate articulation for better occlusal contact on the restoration?

**A:** Though it is difficult to know the exact cause of the high occlusion, if the bite you supplied the lab matches the model, then it is possible the problem may have originated with the bite registration. Next time try taking a centric occlusion bite registration, limited to only the preparation(s) and only the dentition directly opposing the preps. Keeping the bite material off of the remaining teeth will allow you to visually verify that the patient is fully closed in centric occlusion on all the unprepared dentition. Use a firm, flexible material like Futar-D from Kettenbach. The centric bite will accurately record the vertical dimension between the prep and the opposing dentition and help ensure an accurate articulation.

**Q:** Sometimes my posterior, mandibular restorations can be very difficult to seat and have very narrow, point, proximal contacts near the marginal ridge. I am not sure whether I have, or my lab has, more control to address this issue to ensure better draw and broader contacts.

**A:** When preparing a tooth in the lower posterior regions of the mouth where excessive Curve of Spee may be present, I recommend checking for overhanging proximal teeth that can interfere with the angle of insertion and prevent proper draw. Remove any overhanging contact areas that you find and polish them smooth before impressing. This will facilitate draw at seating and reduce the size of potential food traps caused by under-contoured, interproximal surfaces of the restoration below the mesial and/or distal contacts.




## In This Issue

Page 1

- \* **Anterior Communication**
- \* **Centric Bite Registration**
- \* **Draw vs. Curve of Spee**

Page 2

- \* **Veneer Shade Match**
- \* **Impression Accuracy**
- \* **Veneers & Diastemas**



Stephen D. Killian, CDT

## In This Issue

Page 1

- \* **Anterior Communication**
- \* **Centric Bite Registration**
- \* **Draw vs. Curve of Spee**

Page 2

- \* **Veneer Shade Match**
- \* **Impression Accuracy**
- \* **Veneers & Diastemas**

Do you have a question for Steve?

He can be reached at:  
steve@killiandental.com

## Optimal Restorative Success: Chairside Tips

**Q:** Steve, my lab is not always successful matching the shade for ceramic veneer restorations. Can you suggest ways to improve veneer shade matches?

**A:** Hand fabricated porcelain veneers can be very thin and translucent and will transmit undesirable prep colors, if not blocked. I recommend you provide the lab with the stump shade to enable the ceramist to determine the level of porcelain opacity needed. This will ensure the finished shade of the veneer is not altered by the underlying tooth structure after seating. Keep in mind that darker tooth structures require greater preparation depth to ensure adequate porcelain thickness to block the discoloration.

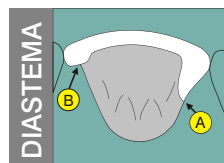
**Q:** I provide my lab with an excellent impression, but sometimes they are unable to "read" the margin. Is there anything I can do, or do I need a new lab?

**A:** You have to remember that the lab does not have the benefit of seeing the stone dies in color like you can see tissue colors in the mouth. Any small amounts of saliva or blood if recorded by the impression can obscure a margin when reproduced in stone. A good lab will let you know when they can't see the margin. Processing an unclear margin may cause the finished restoration to have a number of deficiencies, such as open, short, or over-extended margins.

My suggestions: For margins that are subgingival - the impression material must capture tooth structure below the margin to enable the technician to clearly identify the margin finish line during the die trim procedure. I suggest dual cord or similar techniques. The success rate of the dentist & technician team will be substantially lower with cordless techniques on cases involving subgingival margins. Additionally, prior to impressing, polish rough proximal contacts. This will allow your ceramist to fabricate proper, well contoured broad contacts. One final tip about impressions: quadrant impressions should include the cuspid at a minimum -- to midline is best. This allows your ceramist to inspect wear facets, check guidance, and simulate excursions to minimize lateral interferences.

**Q:** I have a patient with diastemas who is considering veneers to close the gaps. Do you have any suggestions for preparation?

**A:** Diastema closure with veneers can be challenging for the ceramist. To give the ceramist the best chance to fabricate natural contours, I recommend increased proximal preparation. Traditional minimal preparation will not permit proper transitional contours after closure of diastema. Also, prep slightly sub-gingivally at proximal margins to ensure smoother curves and transitional contours between tooth structure and porcelain. See the illustration below:



Increased proximal preparation **A** allows proper contour. Preparation does not permit proper transitional contour after closure of diastema. **B**